

Comparison of Parker-tipped and Murphy-tipped tracheal tubes in Airway Scope-assisted intubation in a manikin

TAKURO SANUKI, SHINGO SUGIOKA, MOTOKO HIROKANE, NAOTAKA KISHIMOTO, YOSHIKO MATSUDA,
and JUNICHIRO KOTANI

Department of Anesthesiology, Osaka Dental University, 1-5-17 Otemae, Chuo-ku, Osaka 540-0008, Japan

Abstract

Purpose. We tested our hypothesis that a Parker-tipped tracheal tube could improve the reliability of tracheal tube passage as compared to a Murphy-tipped tracheal tube during Airway Scope-assisted intubation in a manikin.

Methods. Twenty-seven resident doctors performed Airway Scope-assisted intubations using both tracheal tubes, and the number of times the tracheal tube tip touched the glottis or other laryngeal structures was counted on the Airway Scope monitor.

Results. The incidence of the tracheal tube tip touching the glottis during Airway Scope-assisted intubation using the Parker-tipped tracheal tube (7.4%; 2 of 27 attempts) was significantly less than that obtained using the Murphy-tipped tracheal tube (33.3%; 9 of 27 attempts; $P = 0.039$).

Conclusion. When the advancement of a conventional tracheal tube during Airway Scope-assisted intubation is likely to result in collision with the glottis or other laryngeal structures, the selection of a Parker-tipped tracheal tube is a better option.

Key words Airway Scope · Manikin study · Parker-tipped tracheal tube

Introduction

The Airway Scope system (AWS; Pentax, Tokyo, Japan) is a video laryngoscope for tracheal intubation [1–5]. The AWS can be useful in the management of difficult airways, because it provides a view of the glottis without requiring alignment of the oral, pharyngeal, and tracheal axes [1]. It has a built-in 2.4-inch monitor screen that displays an image from a charge-coupled device attached to the tip of the scope [2]. A single-use blade protects the camera unit from oral contamination and holds a tracheal tube (TT) [3]. Once the target signal

Address correspondence to: T. Sanuki
Received: April 3, 2009 / Accepted: June 22, 2009

shown on the monitor is aligned with the glottic opening, pushing the TT along with the tube guide allows it to pass through the glottis [4]. However, the conventional TT tip often impinges on the glottis or other laryngeal structures when the TT is advanced from the AWS into the trachea [5].

The Parker-tipped TT (Parker Flex-Tip tube; Parker Medical, Highlands Ranch, CO, USA) has a tapered fountain-pen-shaped tip [6–8]. In tracheal intubation with fiberscopes or Bullard laryngoscopes, the Parker-tipped TT has been shown to have easier passage, without colliding with the glottis or other laryngeal structures, when compared to a conventional TT in patients with difficult airway [7, 8]. However, no study to date has shown the utility of the Parker-tipped TT in AWS-assisted intubation. In this study, we tested our hypothesis that the Parker-tipped TT could improve the reliability of TT passage when compared to the most conventional TT—i.e., the Murphy-tipped TT—during AWS-assisted intubation in a manikin.

Materials and methods

As advised by the local research ethics committee, because this volunteer, laboratory-based study did not involve patients, it did not require formal committee approval. Twenty-seven resident doctors, with no prior experience using the AWS, were randomly recruited and tested at their convenience. Informed consent was obtained from all individuals who agreed to participate in this study. The data were made anonymous, and information on the performance of individual participants was not made available to anyone outside the study group.

The principal investigator demonstrated the use of the AWS. An AWS with a preloaded TT was inserted into the mouth of a manikin, the glottic opening was positioned at the centre of the criss-cross mark on the

AWS monitor, and the TT was advanced into the trachea. Participants were then allowed to practice AWS-assisted intubation with each TT once. Next, they performed AWS-assisted intubations using each TT once, in random order. Both TTs used in this study, the Parker-tipped TT and the Murphy-tipped TT (Rusch super safety clear plus tracheal tube; Teleflex Medical, Research Triangle Park, NC, USA), had an internal diameter of 7.0 mm and an external diameter of 9.3 mm.

Primary measurements included the incidence of the TT tip touching the glottis or other laryngeal structures during advancement of the TT into the trachea. TT tip touching was counted on the AWS monitor and the site that the TT tip touched was recorded on a clock face diagram, as in a previous study [8,9]. Additional points of interest were the time required for tracheal intubation and the rate of successful tracheal intubation. Intubation time was recorded from the time of taking hold of the TT-preloaded AWS to lung inflation of the manikin after connecting the TT to a self-inflating bag. Finally, immediately after the two tracheal intubation attempts, participants were asked to rate the difficulty of passage of each type of TT through the vocal cords, using a 100-mm visual analogue scale (VAS; from 0 mm = extremely easy to 100 mm = extremely difficult).

On the basis of a pilot study, a sample size calculation was performed to detect a 35% difference in the incidence of TT tip touching with a type I error of 0.05 and a power of 0.8 for a two-tailed $2 \times 2 \chi^2$ test. The incidence of TT tip touching was analyzed using Fisher's exact test as appropriate. Intubation times and VAS scores were expressed as median values (10th–90th percentile ranges) and analyzed using the Mann-Whitney *U*-test. All tests of significance were two-sided and a *P*-value of <0.05 was considered significant.

Results

All 27 resident doctors completed the study. The incidence of TT tip touching during AWS-assisted intubation using the Parker-tipped TT (7.4%; 2 of 27 attempts) was significantly lower than that observed using the Murphy-tipped TT (33.3%; 9 of 27 attempts; $P = 0.039$). Figure 1 demonstrates the distribution of the tube tip positions on a clock face. When using the Murphy-tipped TT, the points of impingement lay between 12 and 3 o'clock during 7 of the 27 attempts, and with 2 attempts the TT touched the area between 3 and 6 o'clock. When using the Parker-tipped TT, there were only two incidences of contact, both of which lay between 3 and 6 o'clock. Intubation time with the Parker-tipped TT (20.1 s; range, 14.9–31.6 s) was less than that with the Murphy-tipped TT (24.2 s; range,

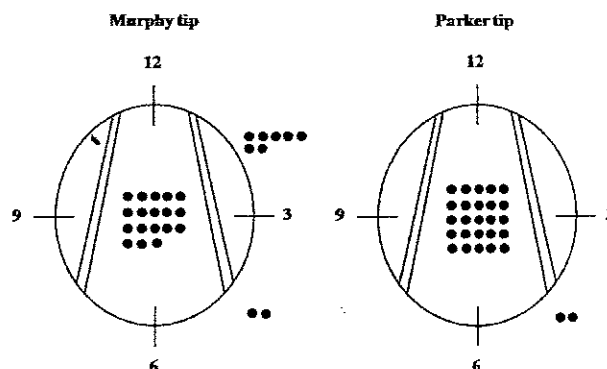


Fig. 1. Distribution of the sites of tracheal tube tip impingement on clock faces. Each dot indicates an individual attempt

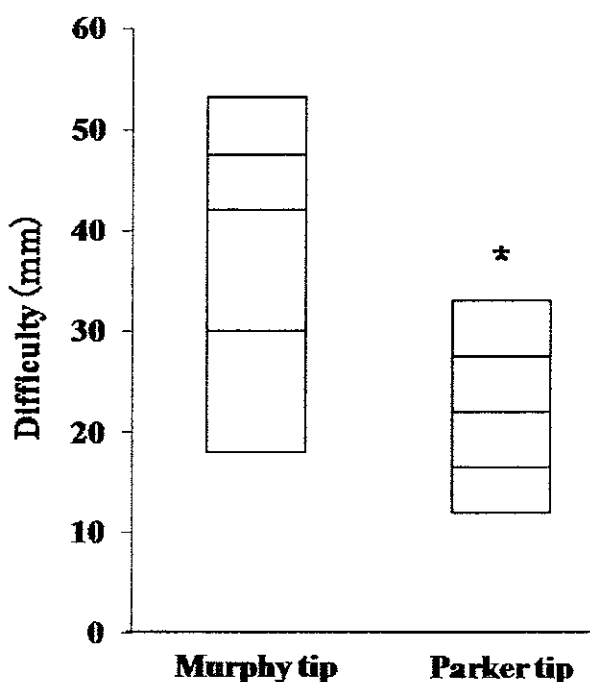


Fig. 2. Difficulty of tracheal tube passage through the glottis. Data are given as percentiles (90, 75, 50, 25, and 10). The asterisk indicates a significant difference between the Murphy- and Parker-tipped tracheal tubes

4.1–41.5 s), although the difference was not statistically significant ($P = 0.191$). With regard to the difficulty of passage of each TT through the vocal cords, rated on the 100-mm VAS scale, the Parker-tipped TT (22 mm; range, 12–33 mm) allowed easier intubations than the Murphy-tipped TT (42 mm; range, 18–53 mm; $P < 0.001$; Fig. 2).

Discussion

Our results show that the incidence of TT tip touching during AWS-assisted intubation using the Parker-tipped TT was less than that observed using the Murphy-tipped TT. Furthermore, the participants rated the Parker-tipped TT as being much easier to pass through the glottis as compared to the Murphy-tipped TT. These results suggest that the Parker-tipped TT could improve the reliability of TT passage, when compared to the conventional Murphy-tipped TT, during AWS-assisted intubation in a manikin. The intubation time for the Parker-tipped TT was shorter than that with the Murphy-tipped TT, although the difference was not statistically significant. A larger study would be needed to determine whether this shorter intubation time for the Parker-tipped TT is actually the case.

Although the Murphy-tipped TT was shown to be acceptable for AWS-assisted intubation in the present study, it was associated with a higher risk of impingement of the tip around the vocal cords. Repeated touching of the glottis or other laryngeal structures, especially in a difficult airway, can cause bleeding or edema and may, in the worst possible case, become a "cannot intubate-cannot ventilate" situation [6]. This would have significant adverse clinical implications in both normal and difficult airways.

The two TTs compared in the present study had the same internal and external diameters, and were made of the same material (polyvinyl chloride; PVC). Moreover, they have roughly the same curve. Therefore, the difference in tip design must be considered to be responsible for the improved TT passage with the Parker-tipped TT.

A previous study by Kristensen [7] showed that during intubation with the aid of a flexible fiberoptic, the use of a Parker-tipped TT resulted in a significantly lower rate of tip touching while passing the tube into the trachea, as compared to results with a Murphy-tipped TT (29%; 11 out of 38 attempts, vs 89%; 34 out of 38 attempts). Suzuki et al. [8] reported that during intubation with a Bullard laryngoscope, the incidence of TT tip touching during intubation using the Parker-tipped TT (5.2%; 1 out of 19 attempts) was significantly less than that obtained using the Murphy-tipped TT (52.6%; 10 out of 19 attempts). We obtained similar results in the present study using the AWS. The study by Suzuki et al. [8] revealed that the most common site of tube impingement when passing a Murphy-tipped TT into the trachea using a Bullard laryngoscope lay between 3 and 6 o'clock on the clock face. Our study showed that the most frequent sites of obstruction during the passage of the Murphy-tipped TT used with the AWS lay between 12 and 3 o'clock on the clock face. Although there are no data to suggest why the tip of the

Murphy-tipped TT most frequently came into contact with the upper right part of the larynx, we surmise that the right-sided opening of the single-use blade for the AWS and the force required to push a TT could possibly affect the direction of TT tip touching with a Murphy-tipped TT.

The present study has a number of limitations. First, all tracheal intubations were performed by inexperienced users. Second, all tracheal intubations were performed using TTs made of PVC. Our results may not be applicable to an experienced user or to TTs made of other materials. Third, all tracheal intubations were performed on a manikin. Although the use of a manikin does not fully reproduce laryngoscopic conditions in patients, it is a popular approach for evaluating and comparing various airway devices, at least in part for ethical reasons [10,11].

In summary, the Parker-tipped TT improved the reliability of TT passage when compared to a conventional TT during AWS-assisted intubation in a manikin. Therefore, when collision with the glottis or other laryngeal structures is of particular concern during the advancement of a conventional TT during AWS-assisted intubation, the selection of the Parker-tipped TT is probably an easy solution to this TT advancement problem.

Acknowledgments. No financial support was obtained for this study. We would like to thank Dr. Hiroki Son (Hirakata City Hospital) for his valuable advice and suggestions.

References

1. Koyama J, Aoyama T, Kusano Y, Seguchi T, Kawagishi K, Iwashita T, Okamoto K, Okudera H, Takasuna H, Hongo K. Description and first clinical application of Air Way Scope for tracheal intubation. *J Neurosurg Anesthesiol.* 2006;18:247-50.
2. Hirabayashi Y, Seo N. Use of a new videolaryngoscope (Airway Scope) in the management of difficult airway. *J Anesth.* 2007;21:445-6.
3. Hirabayashi Y, Seo N. Airway Scope: early clinical experience in 405 patients. *J Anesth.* 2008;22:81-5.
4. Komatsu R, Kamata K, Hamada K, Sessler DI, Ozaki M. Airway scope and StyletScope for tracheal intubation in a simulated difficult airway. *Anesth Analg.* 2009;108:273-9.
5. Ueshima H, Asai T, Shingu K, Inoue H, Hashimoto Y, Enomoto Y, Okuda Y. Use of a gum elastic bougie for tracheal intubation with Pentax-AWS airway scope (in Japanese with English abstract). *Masui (Jpn J Anesthesiol).* 2008;57:82-4.
6. Figueras J, Onrubia X, Sánchez de Merás A, Estruch M, Barberá M. A Parker Flex-Tip tube for fiberoptic nasotracheal intubation in a case of lingual tonsil hypertrophy. *Can J Anaesth.* 2005;52:778-9.
7. Kristensen MS. The Parker Flex-Tip tube versus a standard tube for fiberoptic orotracheal intubation: a randomized double-blind study. *Anesthesiology.* 2003;98:354-8.
8. Suzuki A, Tampo A, Abe N, Otomo S, Minami S, Henderson JJ, Iwasaki H. The Parker Flex-Tip tracheal tube makes tracheal intubation with the Bullard laryngoscope easier and faster. *Eur J Anaesthesiol.* 2008;25:43-7.

9. Shigematsu T, Miyazawa N, Kobayashi M, Yorozu T, Toyoda Y, Morisaki H. Nasal intubation with Bullard laryngoscope: a useful approach for difficult airways. *Anesth Analg*. 1994;79:132-5.
10. Koyama Y, Inagawa G, Miyashita T, Kikuchi T, Miura N, Miki T, Kurihara R, Kamiya Y, Goto T. Comparison of the Airway Scope, gum elastic bougie and fiberoptic bronchoscope in simulated difficult tracheal intubation: a manikin study. *Anaesthesia*. 2007;6:936-9.
11. Miki T, Inagawa G, Kikuchi T, Koyama Y, Goto T. Evaluation of the Airway Scope, a new video laryngoscope, in tracheal intubation by naive operators: a manikin study. *Acta Anaesthesiol Scand*. 2007;51:1378-81.